

The Development of the Premature Infant Chest Wall



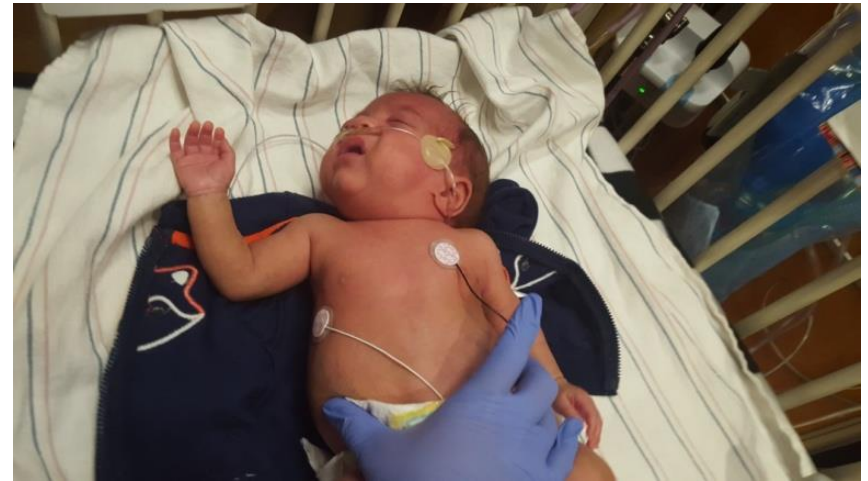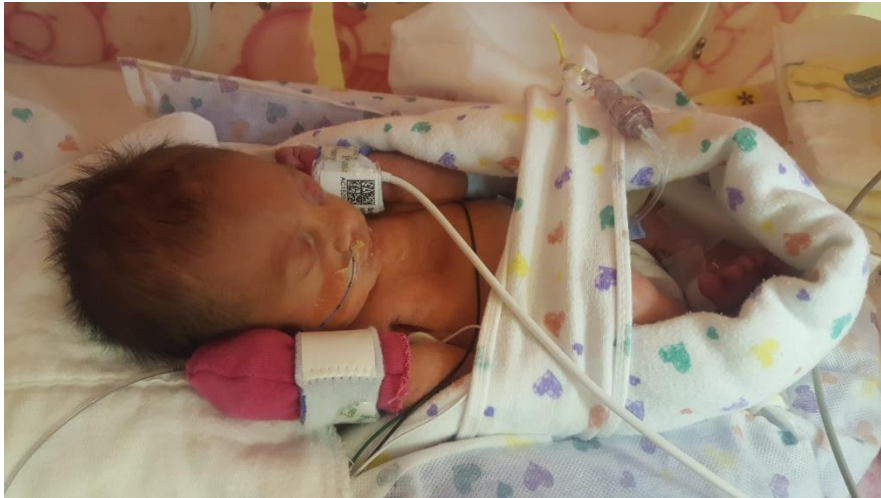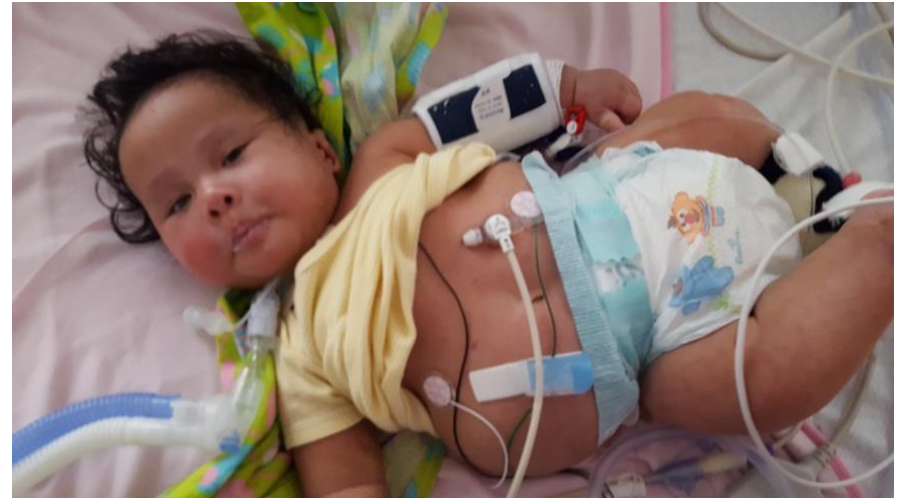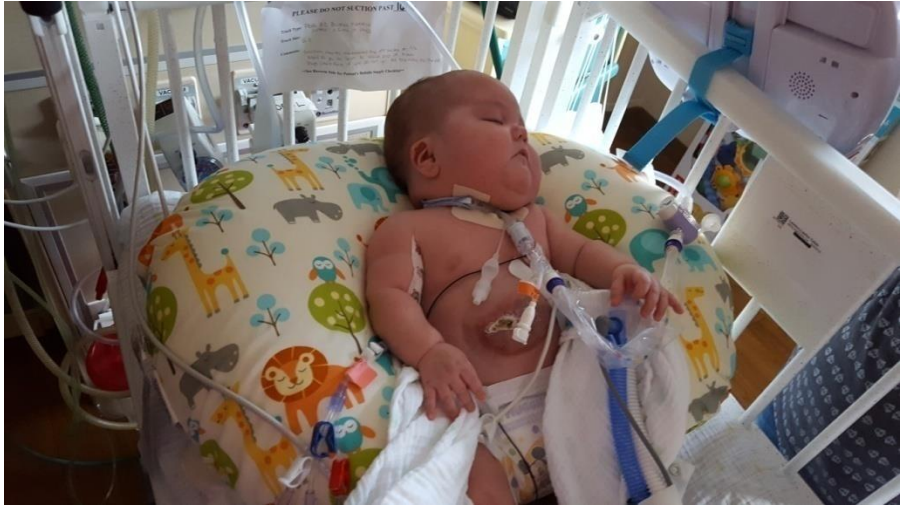**HOLLY SCHIFSKY, OTR/L, NTMTC, CBIS, CNT
CLINICAL SPECIALIST II
UNIVERSITY OF MINNESOTA MASONIC CHILDREN'S
HOSPITAL
LEVEL IV NICU
AUDREY HARRIS VISION CONFERENCE 2017**



Objectives



- Discuss anatomical and kinesiological developmental changes for the newborn chest wall
- Discuss affects of prematurity and pulmonary co-morbidities on chest wall development
- Integrate chest wall movement assessment strategies to maximize infant outcomes
- Understand developmental positioning and handling interventions to reduce chest wall deformities

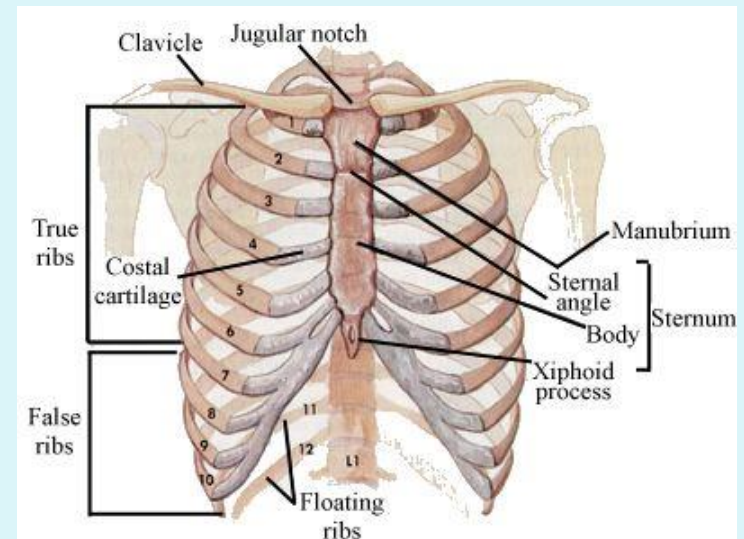




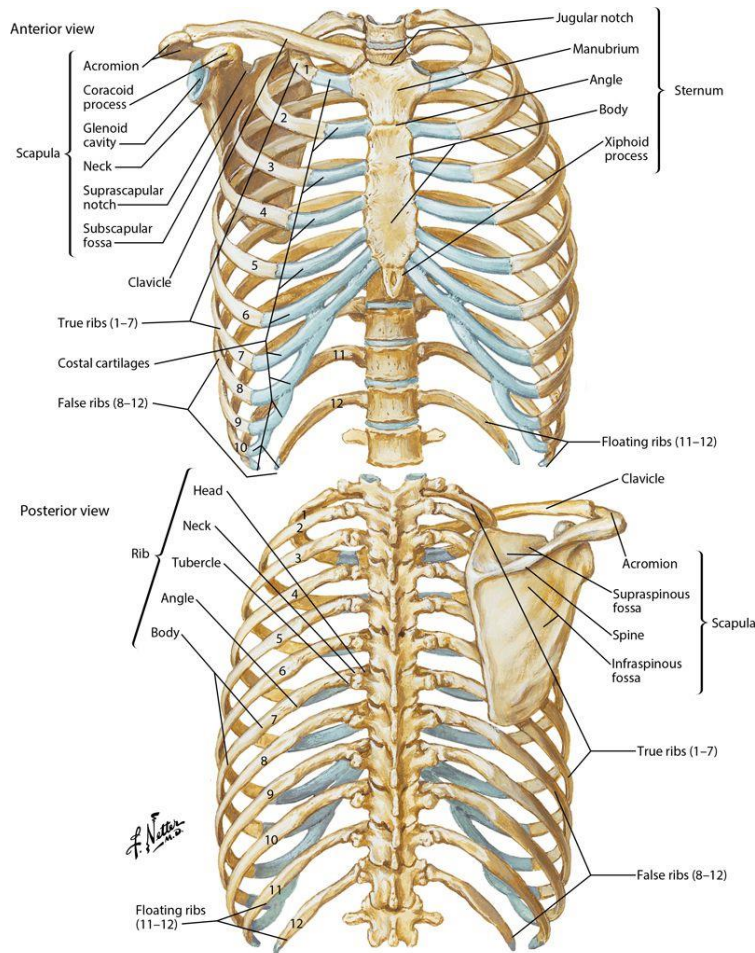
Normal Infant Chest Wall Development



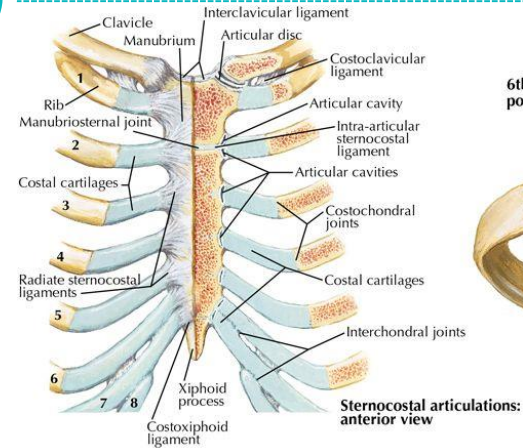
- Primary Influences on Chest Wall Development
 - *Gravity*
 - *Muscle strength*
 - *Muscle tone*
 - *Ability to control intra-thoracic pressure and intra-abdominal pressure*
 - *Integumentary mobility*
 - *Lung health*
 - *Spinal and pelvic alignment*



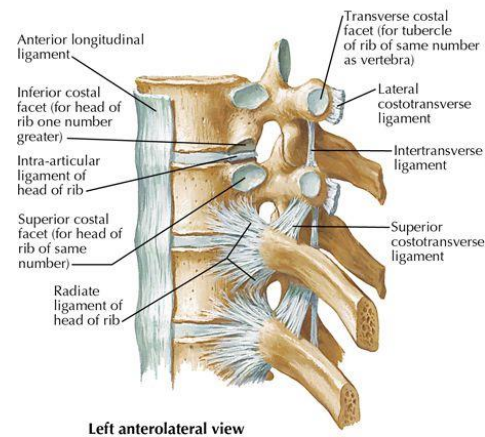
Skeletal Development



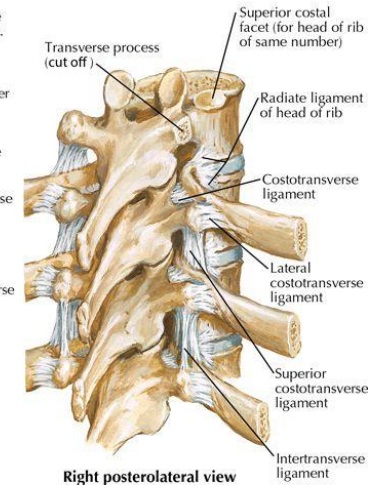
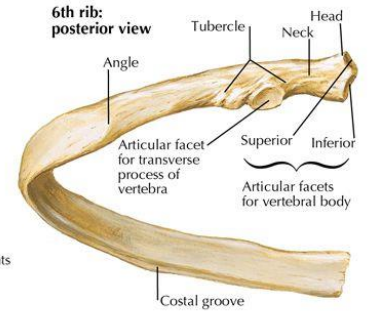
Copyright © Elsevier Inc. www.netterimages.com Netter, Atlas of Human Anatomy, 6e



Note: The head of a typical rib articulates with the superior costal facet of the thoracic vertebra of the same number (by its inferior articular facet), the inferior costal facet of the vertebra above (by its superior articular facet), and the intervertebral disc between the two vertebrae. The costal tubercle articulates with the transverse process of the vertebra of the same number.



Left anterolateral view

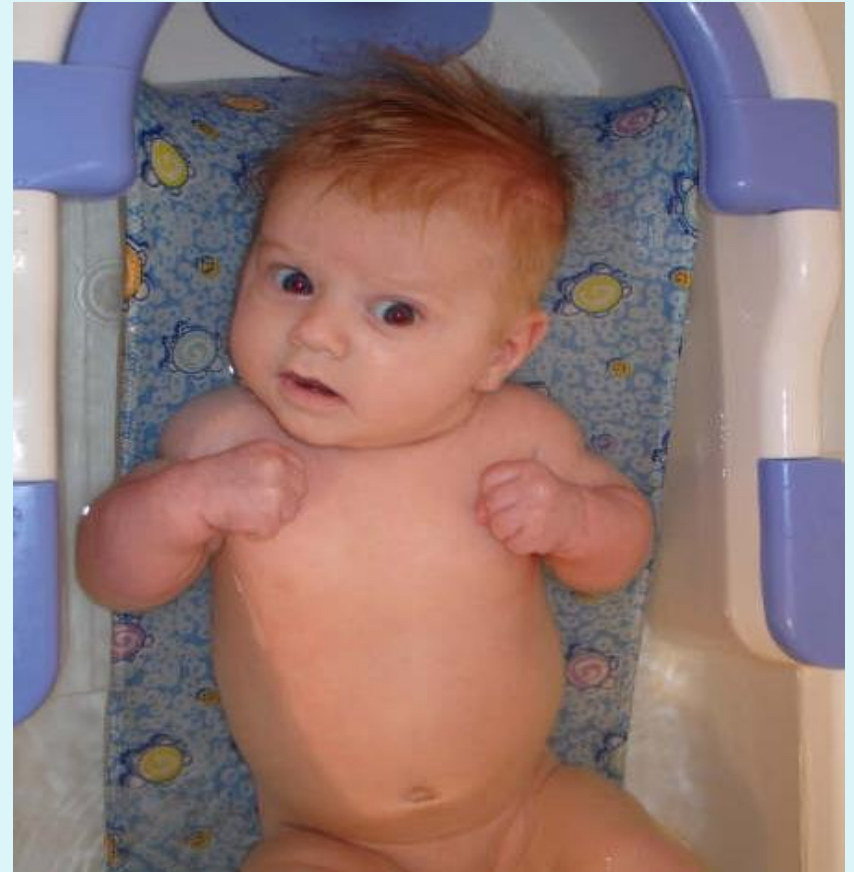


Right posterolateral view

Copyright © Elsevier Inc. www.netterimages.com Netter, Atlas of Human Anatomy, 6e

Key Components: Term infant-3 month

- **Shape**
 - *Triangular, no “neck”, round abdomen*
 - *When one rib moves they all move*
- **Breathing Pattern**
 - *Nose breather*
 - *Diaphragmatic breather, no functional accessory muscles for breathing*



Key Components: 3-6months of age

- Shape

- *More rectangular, increase in upper chest movement/shape, anterior chest wall can move against gravity*

- Breathing pattern

- *Primarily diaphragmatic breather, initial signs of upper chest movement*



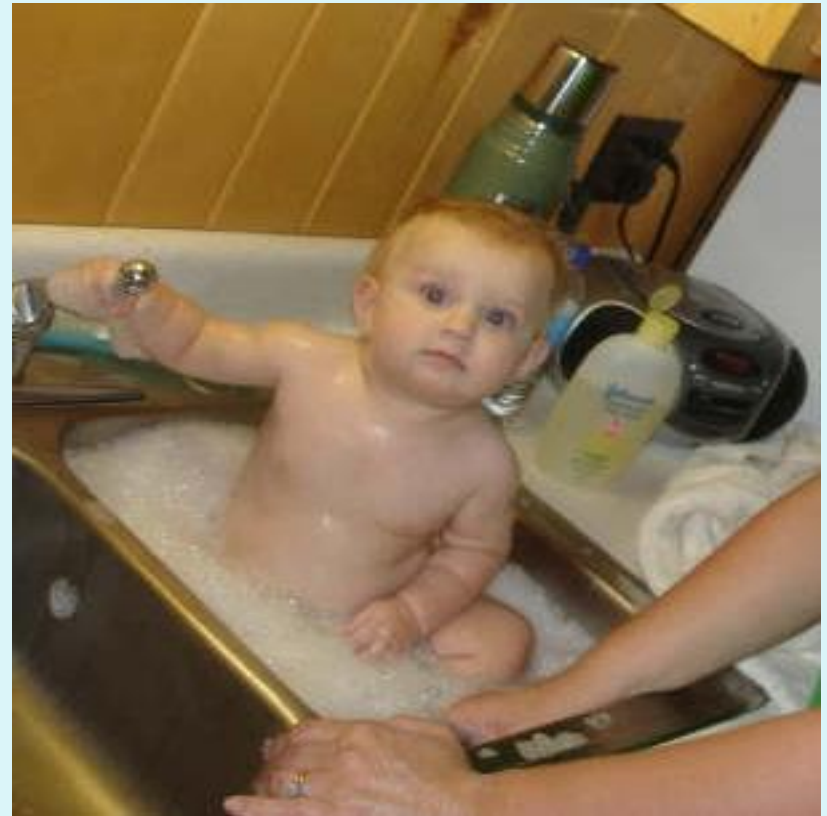Key Components: 6-12 months old

- **Shape**

- *Anti-gravity movement of all planes is possible, cervical elongation, downward rotation of ribs, rectangular shaped chest wall, more elliptical rather than circular chest shape*

- **Breathing pattern**

- *Diaphragm mechanical advantage has improved, accessory muscles available, respiratory reserves have increased, lung size increase 4x since birth*



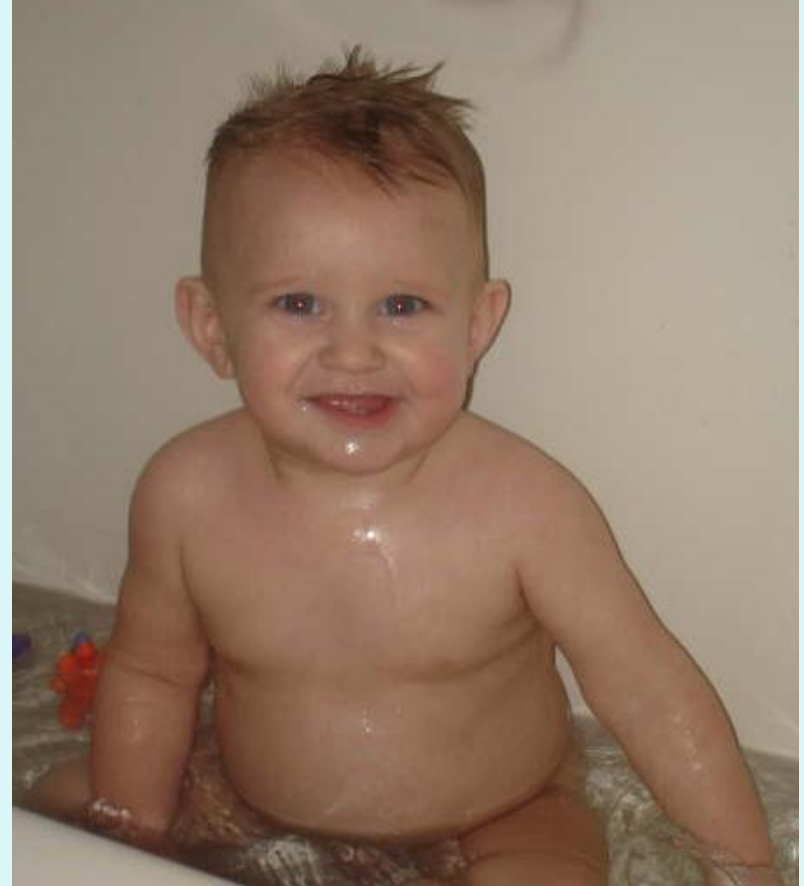
Key Components: Over 12 Months of Age

- **Shape**

- *Vertical elongation of rib cage, scapula in position, more external rotation of shoulders*

- **Breathing Pattern**

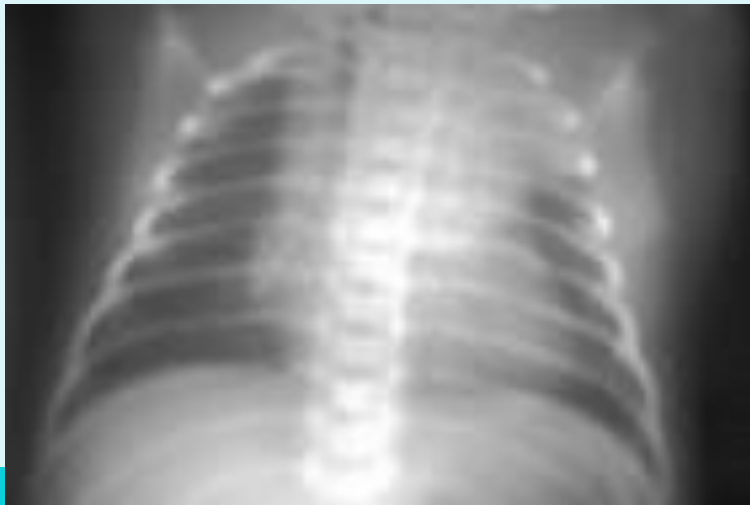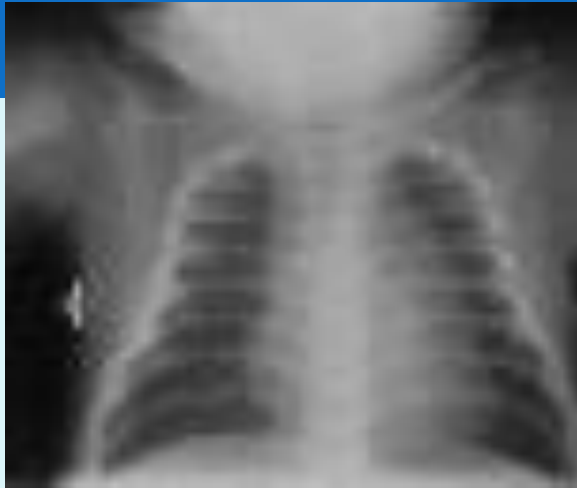- *Refinement of breathing patterns, can meet O₂ demands during activities, rarely holds breath as postural control*



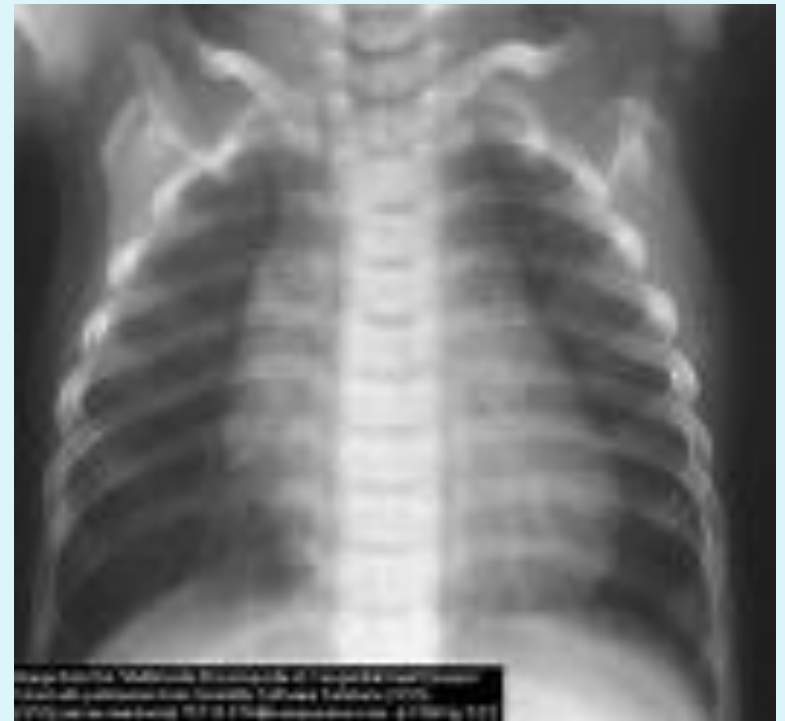Typical Infant Rib rotation



Newborn chest wall

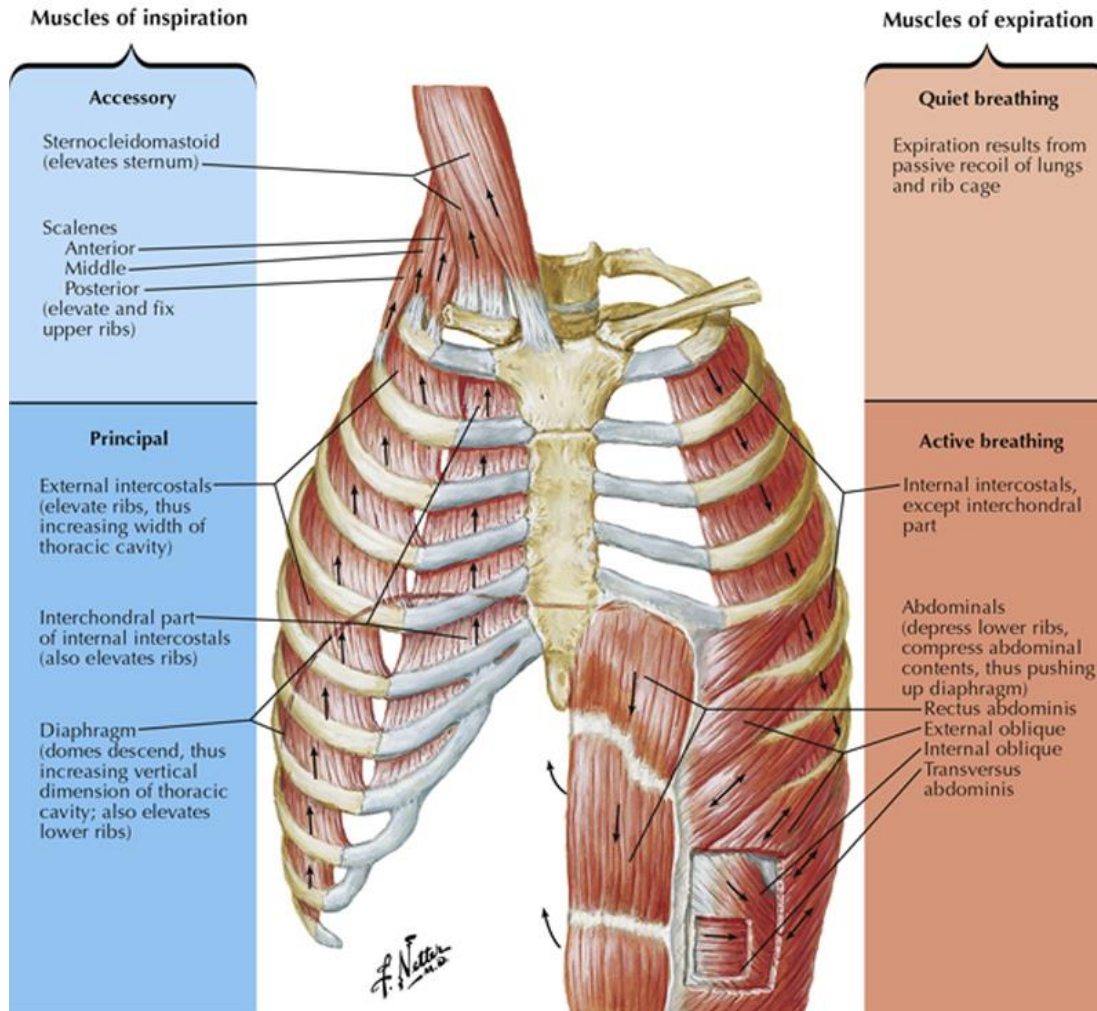


12 month old chest wall



Movement Facilitation

Muscles of Respiration



Affects of Prematurity

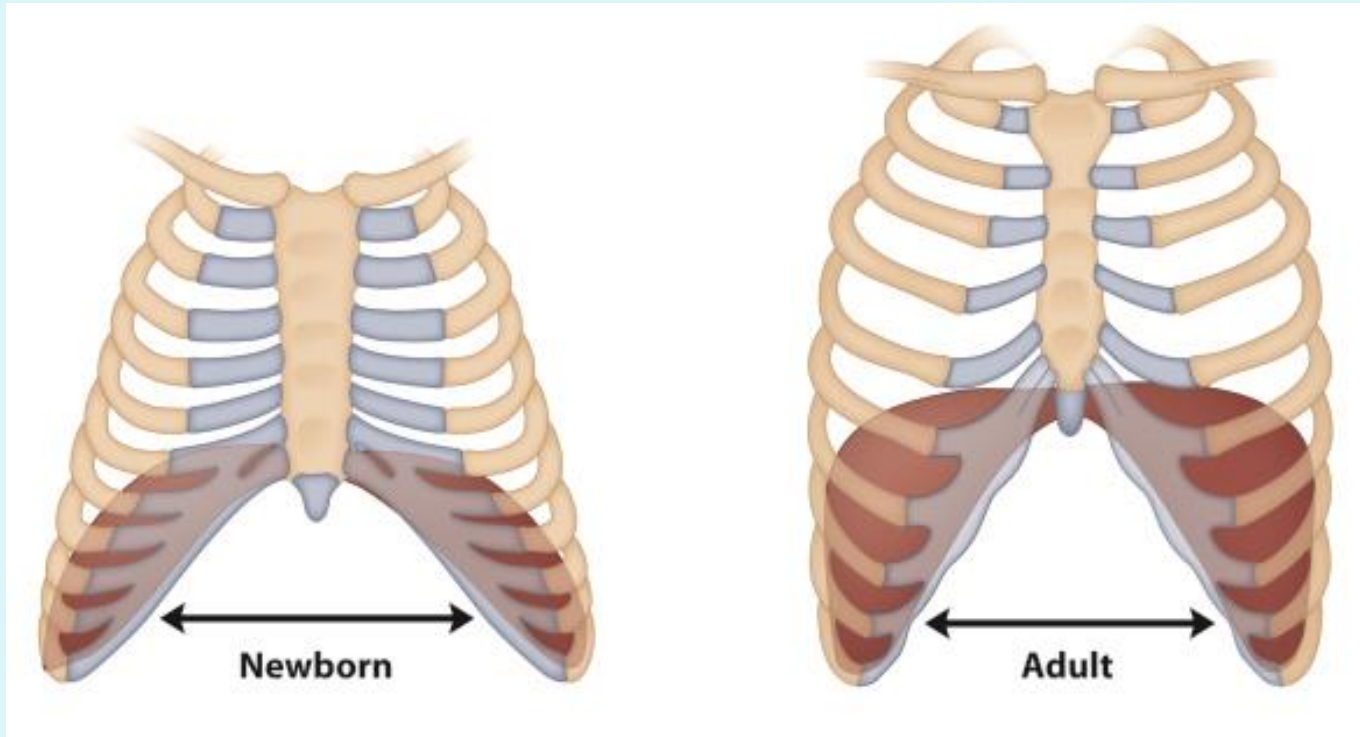


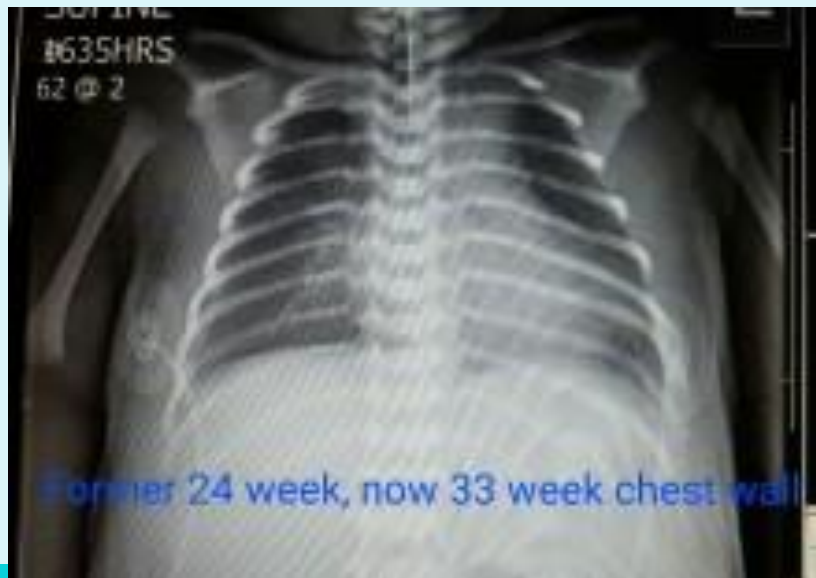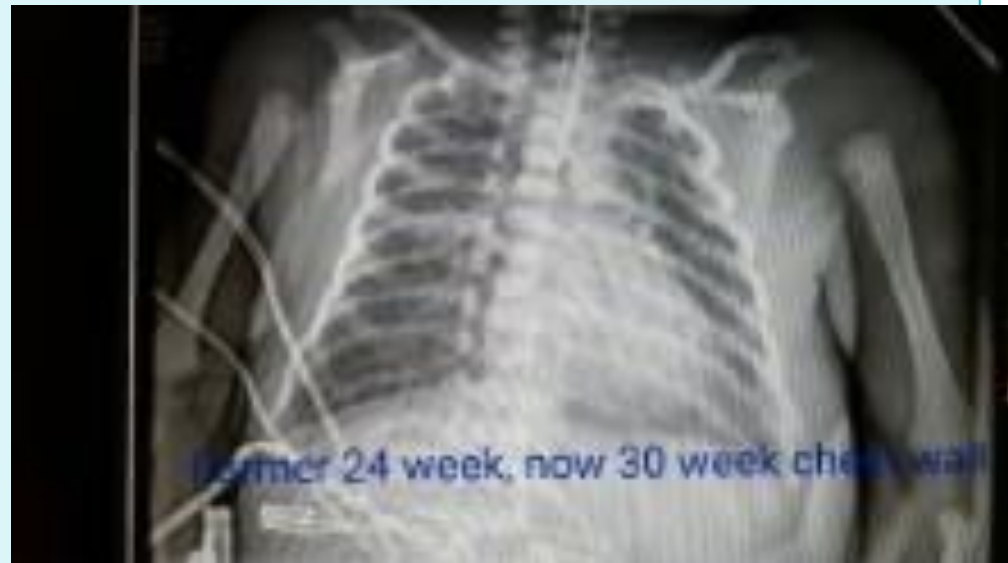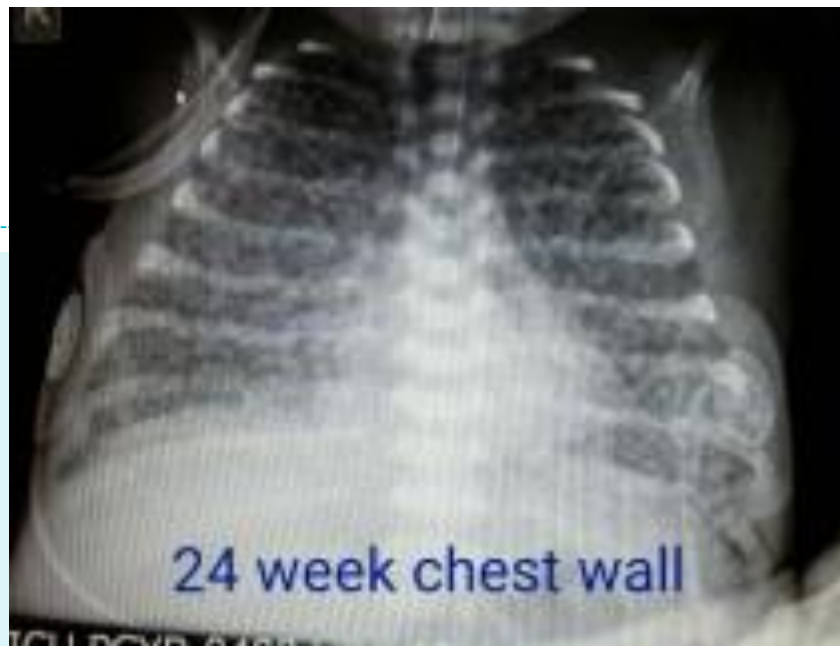Anatomical Differences for the Preterm infant



- Position and shape of the chest wall
 - Reduced area of apposition between the diaphragm and chest wall
- High compliance (mobility) of the chest wall
 - Limited calcification of ribs, so increased diaphragm effort only results in rib retractions
- Low compliance (stiffness) of the lungs
 - Parenchymal problems
 - Airway abnormality
- Differences in muscle fibers and their action

Reduced Area of Apposition





Physiological Challenges for Premature infant (22-31 weeks)



- The diaphragm of the preterm infant has only 10% of Type 1, red fibers required for slower contraction and efficient aerobic endurance activities.
- Limited intercostal contraction, so rely on diaphragmatic descent and increased intra-abdominal pressure
- Younger the gestational age, increased chest wall compliance as poor skeletal ossification
 - Increased rib retractions and/or paradoxical breathing
 - Increased chest wall deformities (pectus excavatum)
 - Poor inspiratory volume to lungs

Mechanics of Breathing in the premature infant (32-36 weeks)



Inhalation:

1. Intercostals: Provide slight upward rotation of the ribcage and isometric control for outward movement of the chest (creates negative intrathoracic pressure)
2. This triggers diaphragm descent and abdominal outward displacement (creates increased intra-abdominal pressure)

Exhalation: should be a passive process

Videos: Breathing Assessment



THE ART OF OBSERVATION

Term Infant Breathing



Premature breathing pattern: 31 week CGA



Premature breathing pattern: former 24 week,
now 34 weeks CGA



Paradoxical Breathing Pattern



Pectus Excavatum: Congenital



Acquired Pectus Excavatum: 30 weeks



Acquired Pectus Excavatum: 33 weeks



Posterior Breathing Pattern at 33 weeks



Micro-Premie: 25 weeks on Jet ventilator



Treatment Considerations



**MONITORING FOR COMPENSATORY
MUSCULOSKELETAL BREATHING PATTERNS**

Intentional Care giving with a Pulmonary Twist



- Auditory input affects on breathing pattern and rate
- Hot/cold input during imposed touch
- Visual gaze and focus

Chest wall considerations for developmental positioning



**POSITIONING FOR DEVELOPMENT AND
POSTURAL DRAINAGE**

Positioning Key Components: 22-34 weeks

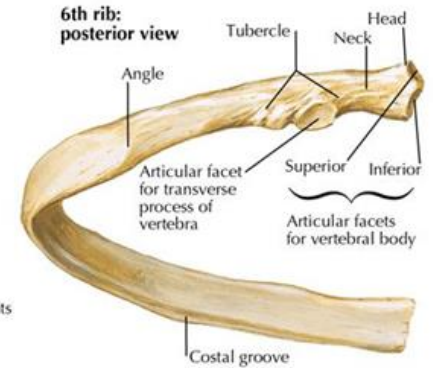
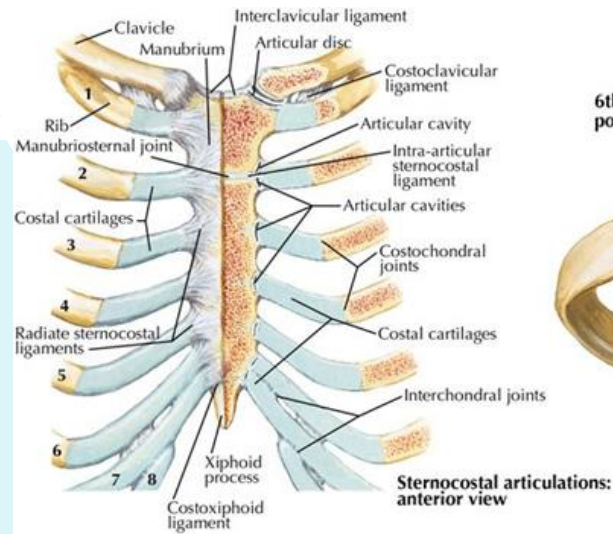


- **Prone**
 - Provides the best thoracoabdominal synchrony and rib cage movement, best length-tension relationship for diaphragm
 - Infant utilizes the static supporting surface to create artificial chest wall stability through weight bearing.
 - Prone support is critical to provide this stability and allow for gravity assisted diaphragmatic movement and secondary posterior chest wall excursion
 - Monitoring of cervical spine and ETT (if applicable) positioning
 - ✦ Neck flexion of 15-30 degrees does not cause airway obstruction; greater than 45 degrees of flexion can occlude airway
 - ✦ Monitor hyperextension
 - Greater than 45 degrees can occlude airway
 - Compensatory response and need more support or position change

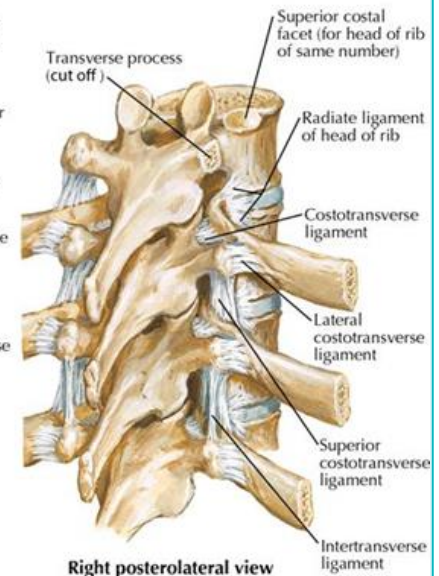
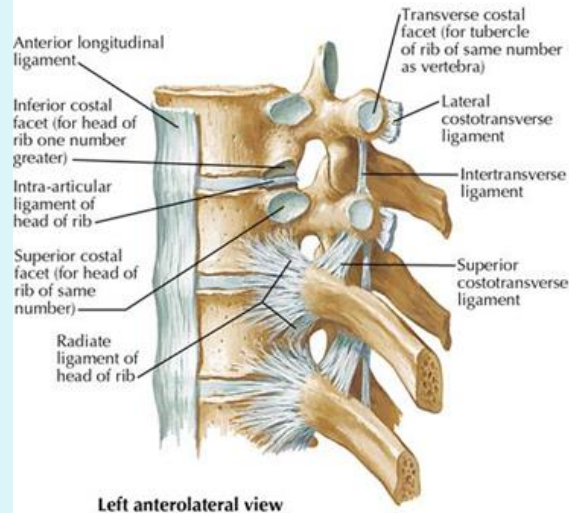
Side lying

- Side lying

- Consideration of cervical spine with slow progression to flexion (not greater than 45 degrees) once extubated to support goals for feeding/swallow, support upright, car seat positioning, etc
- Altering right to left side lying, as the weight bearing ribcage will not have lateral expansion only the unweighted ribcage. Need to prevent asymmetry for future intercostal development
- Nesting support to spine, consider rib insertion at spinal column and need for stabilization
- Facilitated tuck: posterior pelvic tilt to support diaphragm and lower abdominals in flexion for activation
- Hip/LE flexion to provide static support to lateral diaphragm



Note: The head of a typical rib articulates with the superior costal facet of the thoracic vertebra of the same number (by its inferior articular facet), the inferior costal facet of the vertebra above (by its superior articular facet), and the intervertebral disc between the two vertebrae. The costal tubercle articulates with the transverse process of the vertebra of the same number.



Supine: “My nemesis, My friend”



- Similar to side lying: cervical flexion, facilitated tuck
- Allows for bilateral ribcage movement in the lateral plane simultaneously
- Consider affects of gravity on chest wall stability and the inability of the infant to utilize posterior chest wall excursion
 - Increased ventilation strength does not always equate to improved oxygenation (Dimitriou et al 2002)
 - Developmental Specialists always analyze “FORM vs FUNCTION”

Two Person Caregiving: ADL's



- **Diapering:**
 - Use of side lying or prone diapering techniques
 - Stabilizer caregiver with cranial containment and gentle weight transition towards upper chest/shoulders
 - Consideration of not fastening the diaper
- **Positioning changes**
 - Monitoring for chest wall movement, rib retractions, fixed positions
- **Containment**
 - Monitoring of diaphragm descent as infant assumes physiological stability

Functional Progression: 34 weeks and greater



- Transition to supine
- Reduction in developmental positioning devices
- Trunk development
- Arousal, state regulation
- Sleep patterns
- Cry
- Feeding attempts
- Cough
- GI considerations: stooling, reflux, digestion

Form vs Function

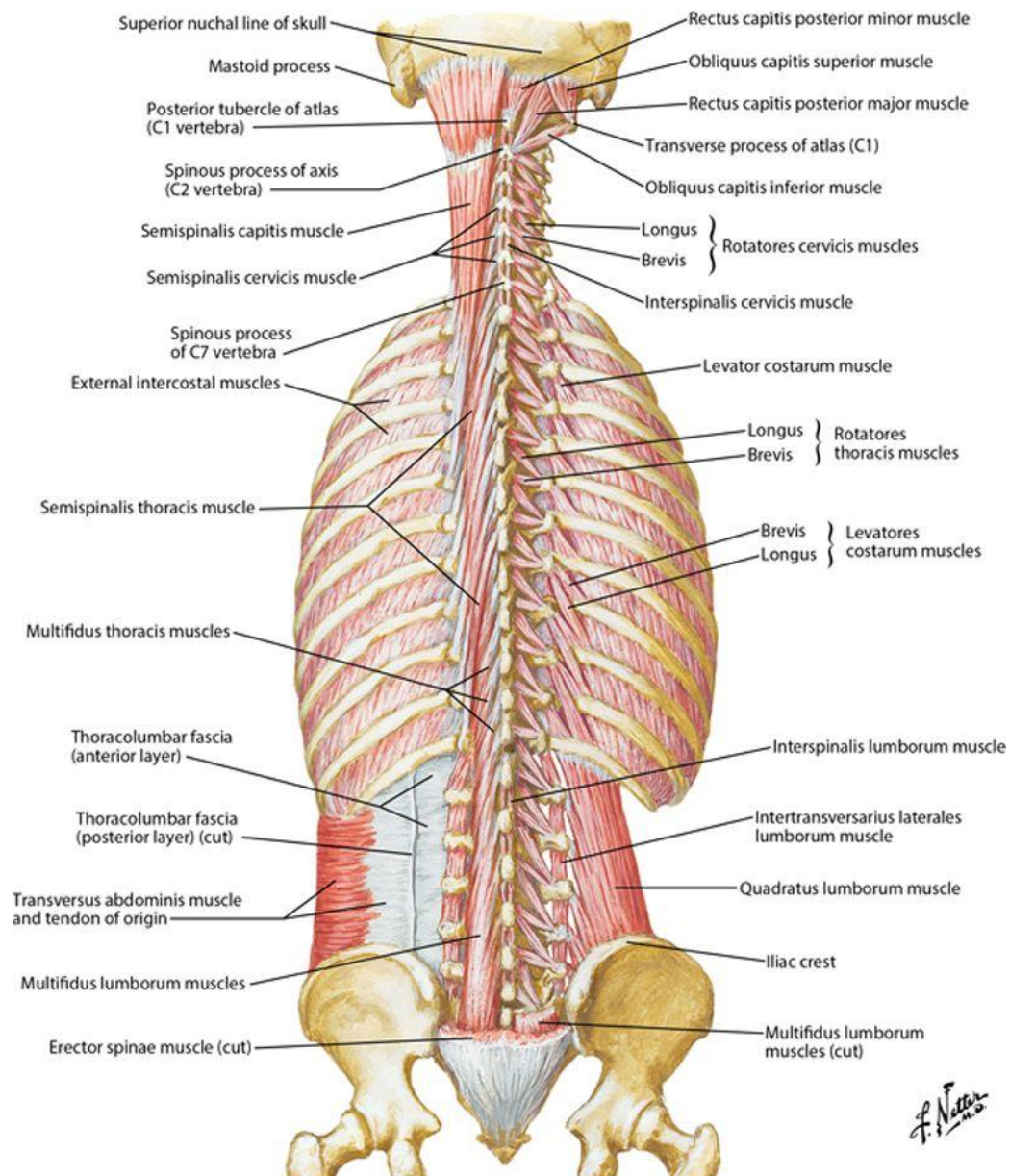


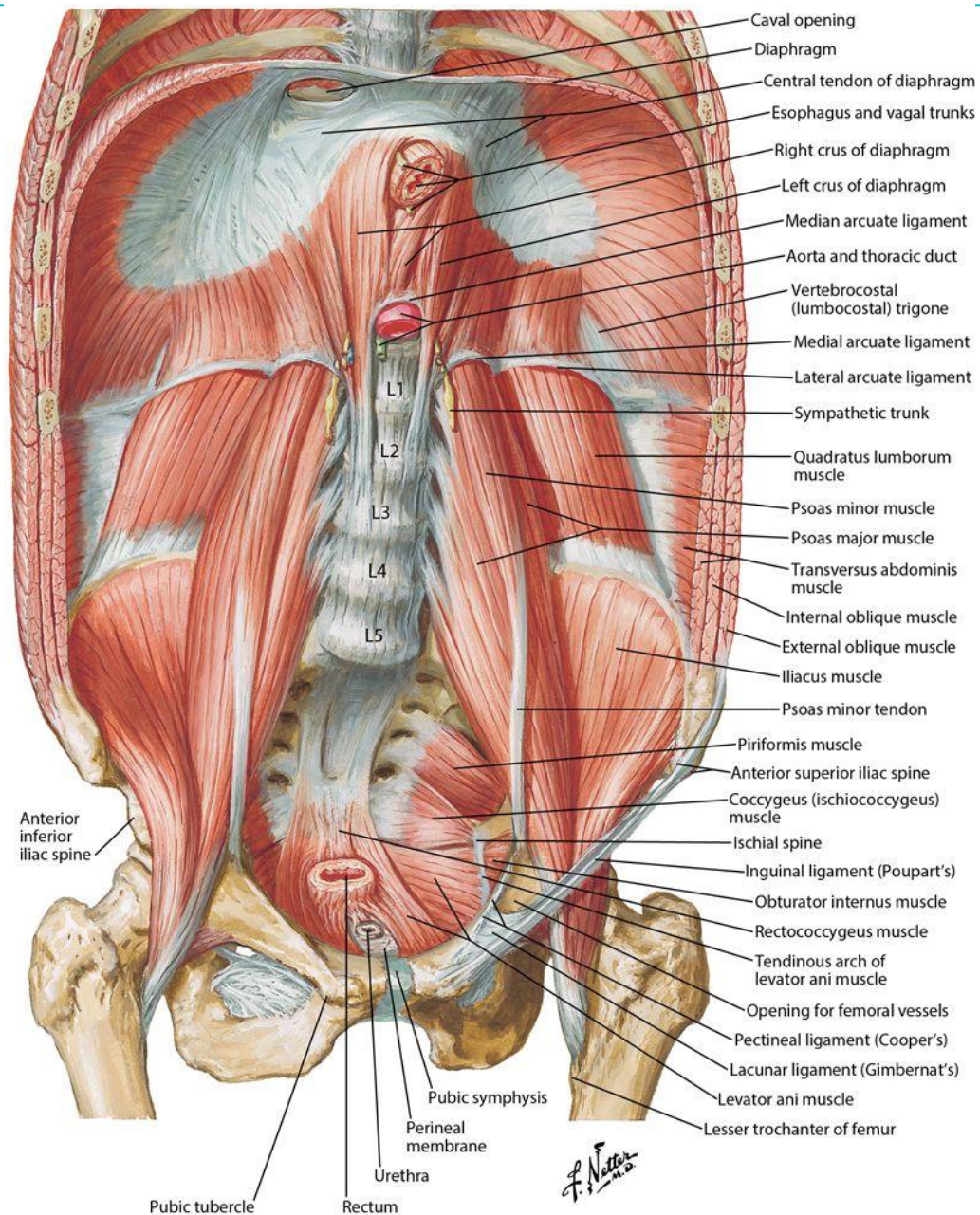
**OUR EXPECTATIONS VS THE INFANT
REALITY**

Critical Reasoning



- Does their breathing pattern support oxygenation needs? (review of blood gases)
- Does their breathing pattern support ventilation needs?
- Does their breathing pattern support developmental expectations for their age?
- Does their breathing pattern support future developmental expectations?





Types of Compensatory Breathing patterns



- Premature infants should develop the ability to strictly utilize diaphragmatic breathing to sustain growth, development, feeding, and motor skills
- Physiological challenges of infants with younger gestational ages hinder this ability
 - Atrophy of the diaphragm
 - Hypotonicity of the preterm infant
 - Poor positioning or medical instability during micro-preemie phase (22-32 weeks) that lead to musculoskeletal impairments



- These factors lead to compensatory musculoskeletal ventilation patterns of breathing for the infant as they continue to develop in the 32-38 weeks
 - Scapular Breathing Pattern: Infant will use this pattern to increase upward mobility of the ribcage for improved tidal volume and Forced Residual Capacity
 - Neck hyperextension; Infant will use neck hyperextension to increase anterior chest wall expansion during inhalation

Facilitated Tuck



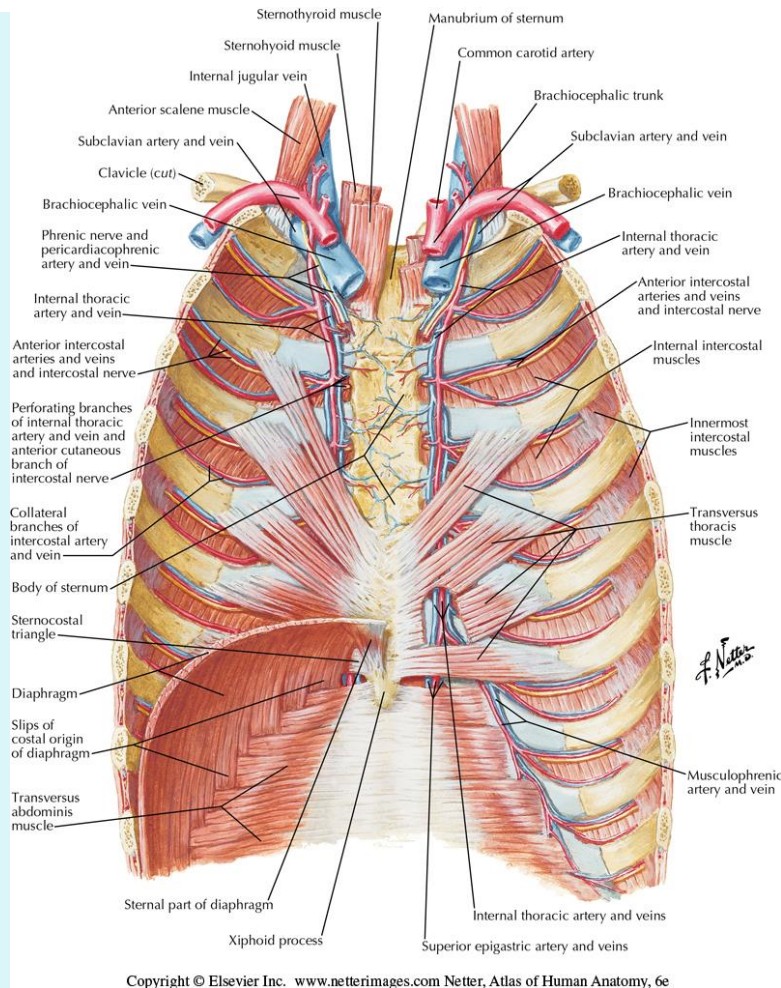
Diaphragmatic facilitation



- Position infant in level supine
- Assess chest wall movement and diaphragm movement
- Transverse abdominis facilitation/activation, dependent upon infant tolerance
 - Transverse abdominis has unique insertion into the fibers of the diaphragm, facilitate of TA allows for increased diaphragm descent and improve thoracic duct stimulation for lymphatic pressure gradient in lower extremities.



- Transverse abdominis plays the most significant role in synchronizing pressure changes with the diaphragm for optimal respiratory movements while simultaneously meeting abdominal pressure needs for postural support



Abdominal Facilitation



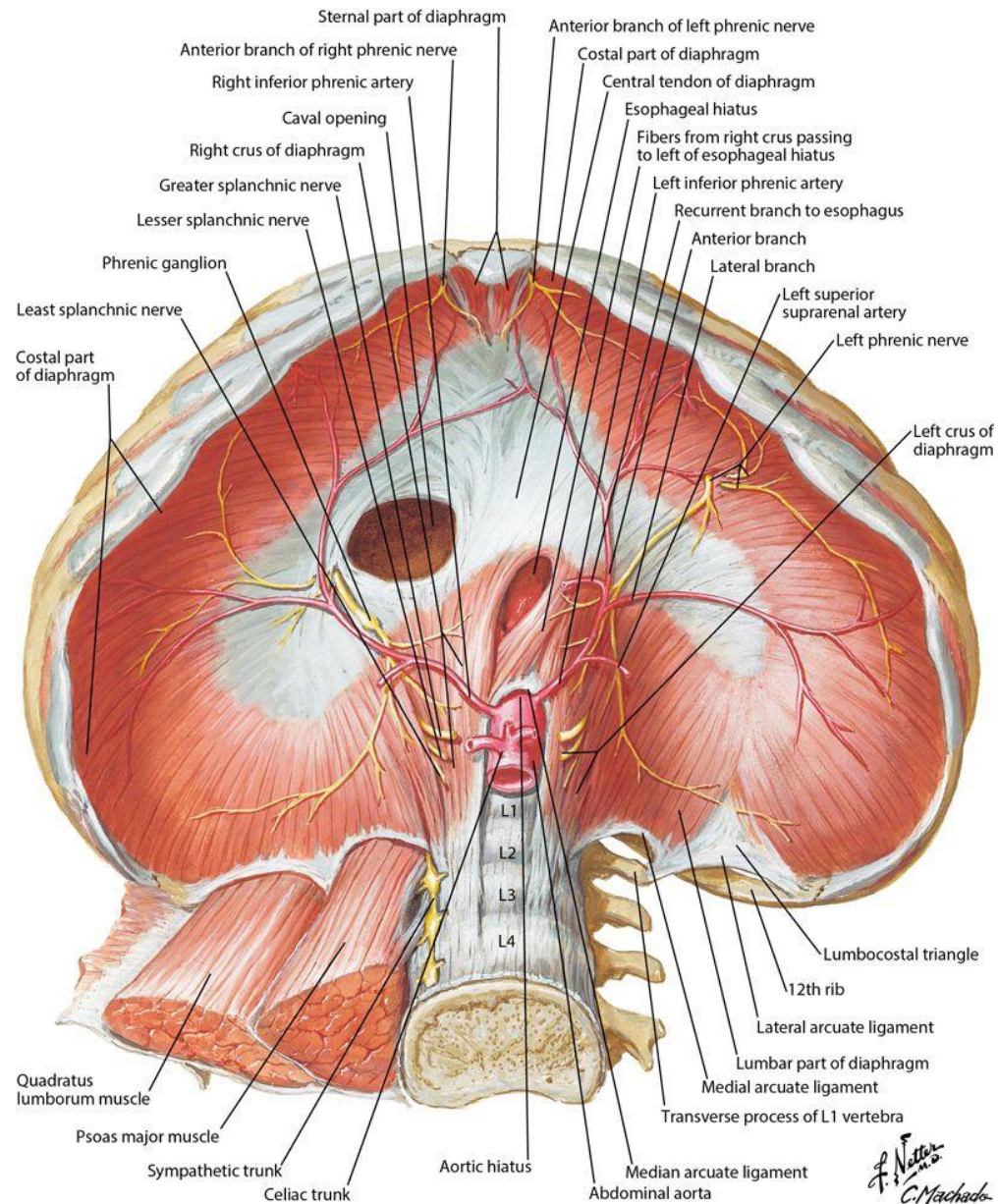
Scapula: “shoulder breather”



- Proper positioning during micro-preemie phase of development
- 32 weeks and older: monitor for excessive accessory muscle breathing pattern; upper trap breathing pattern, rib retractions, subscapularis soft tissue shortening
 - Remember to provide upward rotation of scapula for subscapularis elongation and serratus anterior length-tension development
 - Supraspinatus elongation with hand to face facilitation

Gabriel: Former 26 week now 38 week with BPD





Quadratus Lumborum elongation



- Position the infant in supine on level surface
- Scoop both hands under the infant pelvis and provide slow elongation in lateral trunk extension or pelvic obliquity direction
- Elongate each side with a slight sustained hold
- Scoop infant pelvis off the surface and provide gentle elongation to lumbar spine
- Variation: this can be completed while holding the infant in a supported upright position to increase gravitational pull on the chest wall

Vari: Former 23 week, now 42 week



Facilitation of active prone

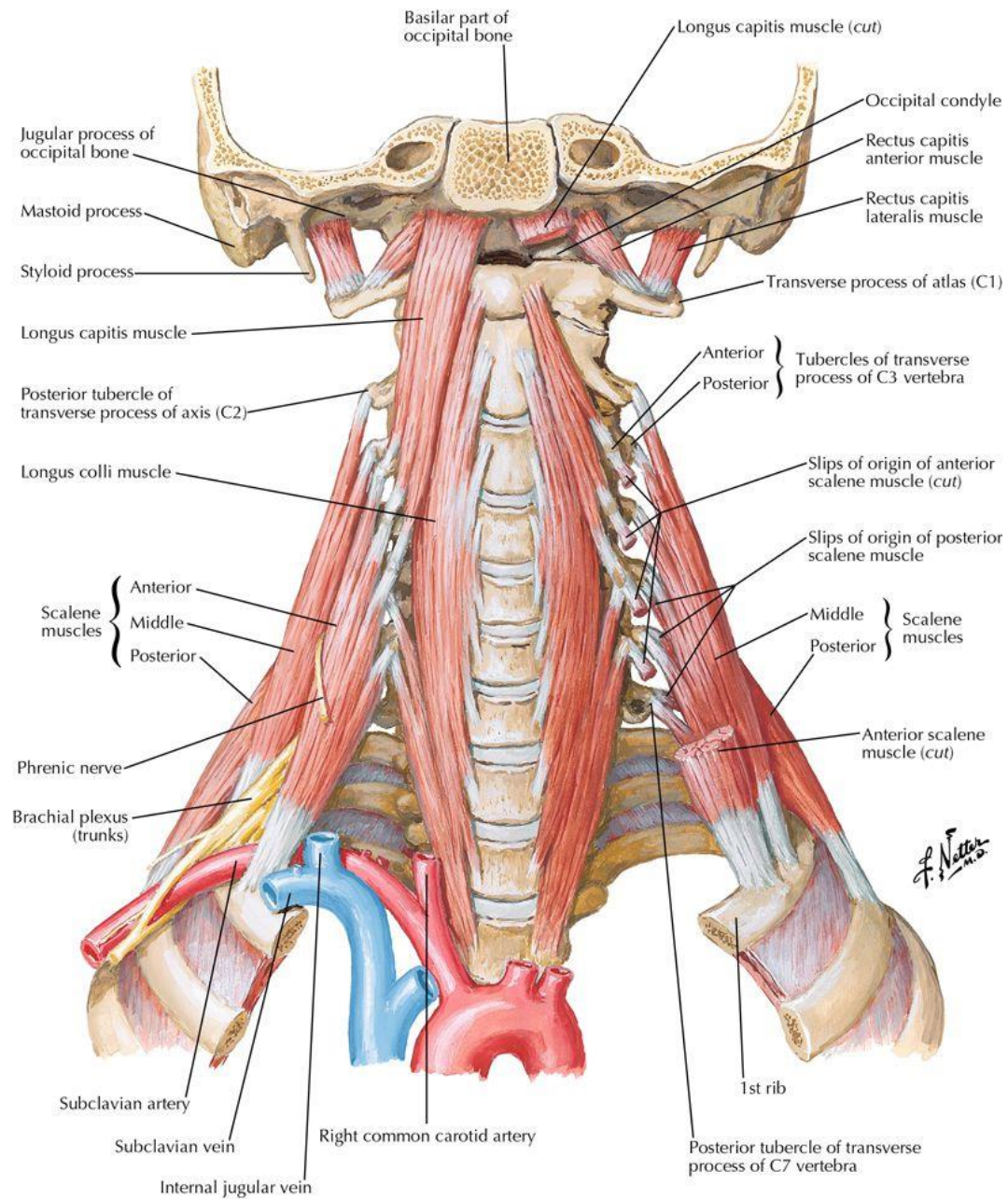


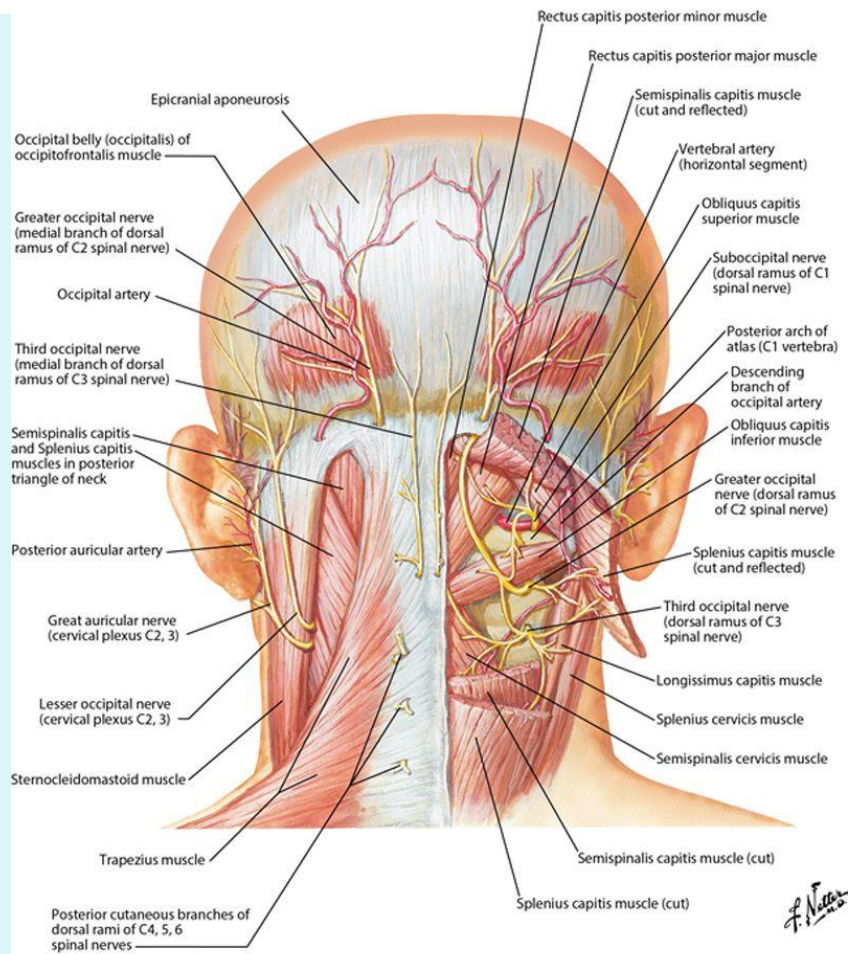
Neck and Jaw: “Neck hyperextension breather”



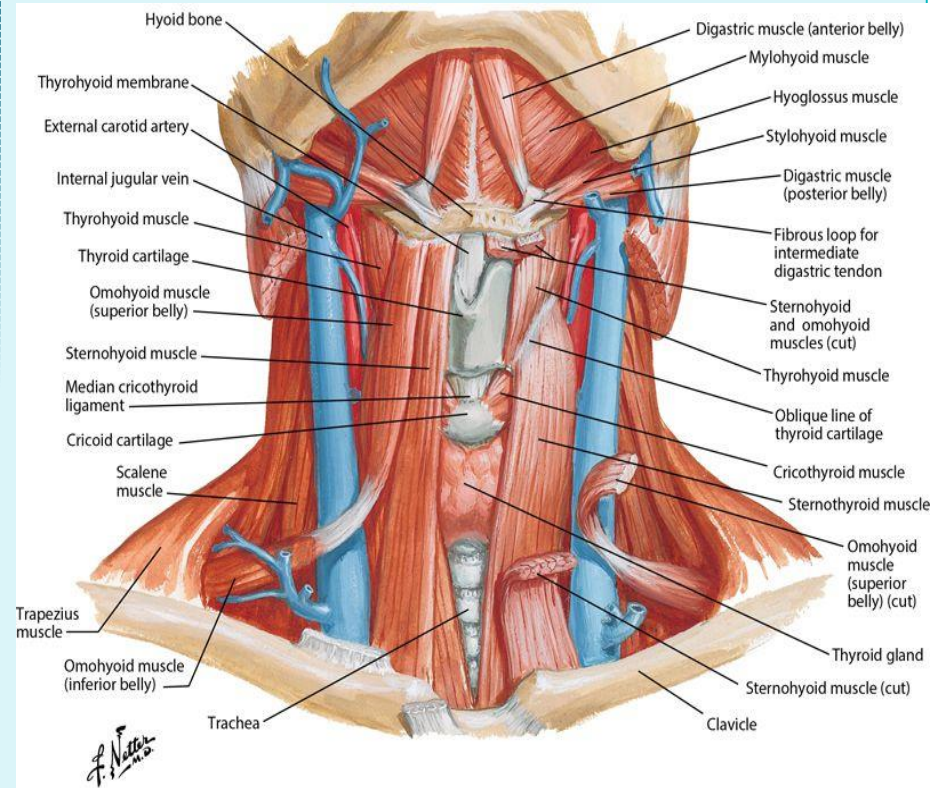
- Assess neck movement with particular attention to:
 - Rectus capitis anterior
 - Rectus capitis lateralis
 - Sternocleidomastoid (clavicular and sternal heads)

Key point: this breathing pattern can alter the alignment of the hyoid bone and its muscular attachments which can significantly change lingual movements, jaw movement, and pre-feeding patterns for suck, swallow, breath





Copyright © Elsevier Inc. www.netterimages.com Netter, Atlas of Human Anatomy, 6e



Copyright © Elsevier Inc. www.netterimages.com Netter, Atlas of Human Anatomy, 6e

Suboccipital facilitation



- Position the infant in flexion swaddled and supported upright, side lying or supine in caregiver arms or on support surface.
- Using your hand, place the palm of your hand at the occipital notch. Provide gentle upward traction to the cervical spine while facilitating chin movement to neutral or a flexed neck position. Infant should transition breathing pattern to posterior ribcage.
- Once in neutral, use of non-nutritive sucking to coordinate this breathing pattern with SSB

Beau: Former 35 week, now 42 week: Chylothorax post-ECMO



Other Considerations ...



- **Scars**
 - Monitor for poor skin pliability secondary to surgical scars, chest tubes, etc
- **Edema**
 - Extremity fluid clearance of lymphatics
 - Increased edema, increased work of breathing and increased effort for diaphragm
- **Gastrointestinal Considerations**
 - GI distention that limits diaphragm descent
 - Constipation
 - Slow GI motility

Re-Imagine your Impact on GERD



- Consideration of thoracic and abdominal pressure
- How are they generated?
- Can this baby physically use their diaphragm to support LES function? (Pandolfino 2007 and 2009)
- Can this baby use pressure gradients to support internal organ function?
- What is the primary reason for GERD? Is it pulmonary related?



Putting it all together...



Taking Breathing to the Next Level...



References



- Greenspan JS, Miller TL, Shaffer TH. 2005. The neonatal respiratory pump: a development challenge with physiologic limitations. *Neonatal Network*. Vol. 24, No. 5, Sept/Oct 2005.
- Trittman JK, Nelin LD, Klebanoff MA. 2013. Bronchopulmonary dysplasia and neurodevelopmental outcome in extremely preterm neonates. *European Journal Pediatrics*. (2013) 172: 1173-1180.
- Colin, AA, McEvoy C, Castile R. Respiratory morbidity and lung function in preterm infants of 32 to 26 weeks gestational age. *Pediatrics*. 2010; 126; 115.



- Gaultier C. Respiratory muscle function in infants. *European Respiratory Journal*. 1995; 8; 150-153.
- Hutton GJ, VanEyckern LA, Latzin P, et al. Respiratory muscle activity related to flow and lung volume in preterm infants compared with term infants. *Pediatric Research*. 2010. Vol. 68, No. 4
- Massery M. Chest development as a component of normal motor development: implications for pediatric physical therapists. 1991. *Pediatric Physical Therapy*.



- Fox, M., and Molesky, M. (1990) The effects of prone and supine positioning on arterial oxygen pressure. *Neonatal Network*, 8(4), 25-29.
- Fox, R.E., Viscardi R.M. Taciak, V.L, Niknafs, H. and Cinoman, M.I., (1993). Effect of position on pulmonary mechanics in healthy preterm newborn infants. *Journal of Perinatology*, 8(3), 205-211.
- Dimitriou, G., Greenough, A. Pink, L., McGhee, , A. Hickey, A., and Rafferty, G.F. (2002) Effects of posture on oxygenation and respiratory muscle strength in convalescent infants. *Archives of Disease in Childhood, Fetal, and Neonatal Edition*, 86, F147-F150.



- Pandolfino Validation of criteria for the definition of transient lower esophageal sphincter relaxations using high-resolution manometry. Neurogastroenterology and Motility · July 2016
- Borowitz, Kathleen. “Gastroesophageal Reflux in Infants” power point presentation.
- Brunherotti NAA, Martinex FE. Response of oxygen saturation in preterm infants receiving rib cage stabilization with an elastic band in two body positions: a randomized clinical trial. Braz J Phys Ther. 2013 Mar-Apr; 17(2); 105-111.



- Rehan, V; Makashim, J.; Gurman, Rubin, L. Effects of the supine and prone position on diaphragm thickness in healthy term infants. *Arch Dis Child* 2000; 83: 234-238
- Oberg, G; Campbell, S; Girolami, G. Study protocol: an early intervention program to improve motor outcome in preterm infants; a randomized controlled trial and a qualitative study of physiotherapy performance and parental experiences. *BMC Pediatrics* 2012; 12:15.



- Arjan, B; Pas, C; Kamlin, J; et al. Breathing patterns in preterm and term infants immediately after birth. *Pediatric Research*. Vol 65, No. 3, 2009
- Giannantonio, Carmen et al. Chest physiotherapy in preterm infants with lung diseases. *Italian Journal of Pediatrics* 2010; 36:65.
- Keens TG, et al. 1978. Developmental pattern of muscle fiber types in human ventilatory muscles. *Journal of Applied Physiology* 44(3); 909-913
- Powers SK, Kavazis AN, Levine, S. 2009. Prolonged mechanical ventilation alters diaphragmatic structure and function. *Crit Care Med* 37: S347-S353.
- Litman, Ronald. *The Basics of Pediatric Anesthesia*. Published Dec. 2014; Chapter 2.